

Maintaining the insulin dosage when starting sodium-glucose cotransporter-2 inhibitors can be a good practice

Mantener la dosis de insulina cuando iniciamos un iSGLT2 puede ser una buena práctica

To the Editor,

We read with great interest the comprehensive review by Llorens on the “Early use of sodium–glucose cotransporter 2 inhibitors (SGLT2i) in patients with heart failure seen in the emergency department.”¹ The article details the evidence on SGLT2i and heart failure, mentioning their mechanism of action and safety data. It also offers specific guidelines to assist with the initiation and/or maintenance of SGLT2i in patients with acute heart failure. We would like to share our opinion regarding the proposed reduction of insulin dosage when initiating SGLT2i therapy.

A serious but very rare complication associated with SGLT2i is diabetic ketoacidosis (DKA). Among the proposed mechanisms, it is postulated that the inhibition of glucose reabsorption in the proximal tubule induced by these drugs, in a patient with hypoinsulinemia, would stimulate an increase in counter-regulatory hormones, lipolysis, and ketogenesis. With greater urinary glu-

cose loss, there is less stimulus for insulin secretion; in other words, both glucose and insulin levels are reduced, favoring ketogenesis.

Patients at highest risk for this complication are those with a marked insulin deficit — namely, patients with type 1 diabetes mellitus when insulin doses are reduced, or those with type 2 diabetes mellitus and poor pancreatic reserve and/or limited glycogen stores, including cachectic patients with low muscle mass or liver disease; individuals with early-onset adult diabetes who required insulin soon after diagnosis; and type 2 diabetics on insulin therapy (particularly those with long disease duration and poor glycemic control).

Of note, many of the reported cases of DKA associated with SGLT2i have occurred in the context of reduced caloric intake or insulin dose, since these factors act synergistically to trigger ketogenesis, as previously reported.^{2,3}

Therefore, contrary to what some protocols suggest, insulin therapy should not be routinely reduced when starting SGLT2i in diabetic patients; it should only be adjusted in specific cases where tight glycemic control poses a risk of hypoglycemia after adding a new antidiabetic agent. Even then, the incidence rate of hypoglycemia with SGLT2i is very low, and these drugs are generally well tolerated in both diabetic and non-diabetic patients.

Another important point to enhance the safe use of

these agents is that, aside from reduced insulin or caloric intake, other precipitating factors for DKA include acute illness, volume depletion, or intense exercise. The emergency physician should assess whether continuation of SGLT2i is appropriate in such situations.

Finally, awareness of these precipitating factors and identification of high-risk patients will help prevent DKA and guide appropriate strategies. These may include initiating SGLT2i at lower doses in at-risk individuals or providing diabetes education that includes specific training in ketosis prevention and management, as well as maintaining an adequate carbohydrate intake without reducing insulin doses.⁴⁻⁷

Note of the editors: This is a BOWMAN-generated English translation of the officially indexed Spanish-language article, which should be cited as *Rev Esp Urg Emerg*. 2024;3:67-68. In this translated version, the editors have supervised the process; however, it cannot be ruled out that some errors resulting from the artificial intelligence translation process may have gone unnoticed.

REFERENCES

- Llorens P. Uso precoz de los inhibidores del cotransportador de sodio-glucosa tipo 2 (iSGLT2) en pacientes con insuficiencia cardíaca atendidos en urgencias. *Rev Esp Urg Emerg*. 2023;2:164-9.
- Modi A, Agrawal A, Morgan F. Euglycemic Diabetic Ketoacidosis: A Review. *Curr Diabetes Rev*. 2017;13:315-21.
- Musso G, Gambino R, Cassader M, Paschetta E. Efficacy and safety of dual SGLT 1/2 inhibitor sotagliflozin in type 1 diabetes: meta-analysis of randomised controlled trials. *BMJ*. 2019; 365:l1328.
- Musso G, Saba F, Cassader M, Gambino R. Diabetic ketoacidosis with SGLT2 inhibitors. *BMJ*. 2020;371:m4147.
- Goldenberg RM, Berard LD, Cheng AYY, Gilbert JD, Verma S,

Authors:

Esther Álvarez-Rodríguez^{1,2}
Marina Gil Mosquera^{2,3},
Pablo Matías Soler^{2,3}.

Filiación de los autores:

¹Servicio de Urgencias, Hospital Universitario Severo Ochoa, Leganés, Madrid, Spain.

²Grupo de Trabajo SEMES Diabetes, Endocrinología y Metabolismo.

³Servicio de Urgencias, Hospital Universitario Clínico San Carlos, Madrid, Spain.

E-mail:

diabetes@gruposemes.org

Ethical Responsibilities:

All authors have confirmed their authorship, the nonexistence of external funding, and the maintenance of confidentiality and respect for patients' rights in the author's responsibilities document, publication agreement, and assignment of rights to *Revista Española de Urgencias Emergencias*.

Editor in Charge:

Guillermo Burillo-Putze.

Woo VC, et al. SGLT2 Inhibitor-associated Diabetic Ketoacidosis: Clinical Review and Recommendations for Prevention and Diagnosis. Clin Ther. 2016;38:2654-64.e1.

6. Dizon S, Keely EJ, Malcolm J, Arnaout A. In-

sights Into the Recognition and Management of SGLT2-Inhibitor-Associated Ketoacidosis: It's Not Just Euglycemic Diabetic Ketoacidosis. Can J Diabetes. 2017;41:499-503.

7. Danne T, Garg S, Peters AL, Buse JB, Mathieu

C, Pettus JH, et al. International Consensus on Risk Management of Diabetic Ketoacidosis in Patients With Type 1 Diabetes Treated With Sodium-Glucose Cotransporter (SGLT) Inhibitors. Diabetes Care. 2019;42:1147-54.

Hydrogen peroxide use in clot obstructed urinary catheter

Uso de peróxido de hidrógeno H_2O_2 en obstrucción de sonda vesical por coágulos

To the Editor,

Complications in patients with indwelling urinary catheters are a common reason for emergency department visits, one of them being catheter obstruction. Obstruction is most often caused by blood clots resulting from urological procedures, radiation cystitis, percutaneous lithotripsy, or bladder tumors. Manual irrigation is usually sufficient to clear the catheter, but in some cases, repeated obstruction causes significant discomfort. Hydrogen peroxide (H_2O_2) has been shown to be a useful and safe agent for dissolving blood clots, as it reduces clot adhesion.

We present the case of a 73-year-old man with a past medical history of bladder tumor treated with chemotherapy and radiotherapy, who developed secondary radiation cystitis. The patient, with a 3-way Foley catheter, presented with pain and difficulty urinating after 3 days of hematuria

without clots. Physical examination was unremarkable except for suprapubic pain and a palpable bladder globe. Laboratory testing showed acute renal impairment (creatinine 4.5 mg/dL; previous 0.93 mg/dL), prompting a bladder ultrasound to rule out obstructive uropathy. The ultrasound showed no obstruction but revealed a heterogeneous intravesical structure measuring 7.5 cm × 5.7 cm × 6.7 cm with no Doppler flow, consistent with a blood clot (Figure 1). After manual irrigation failed to restore flow, 50 mL of 3% H_2O_2 diluted in 200

mL of normal saline was instilled through the catheter following analgesia to prevent pain associated with oxygen release from the reaction of H_2O_2 with the clot. After one instillation and subsequent manual irrigations with clot extraction, the catheter became permeable, and the clot had disappeared on repeat ultrasound. The patient was admitted to urology for cystoscopy, which ruled out active intravesical bleeding; the diagnosis of radiation cystitis persisted. Intravenous fluids were started, and renal function normalized. The final diagnosis

Authors:

Santiago Toranzo Nieto^{1,2}, José Ramón Casal Codesido¹, Daniel Rodríguez Álvarez¹

Filiación de los autores:

¹Servicio de Urgencias, Hospital El Bierzo, Ponferrada, León, Spain.

²Grupo de Trabajo SEMES-MIR Castilla y León, Spain.

E-mail:

santitorazonieto@gmail.com

Ethical Responsibilities:

All authors have confirmed their authorship, the nonexistence of external funding, and the maintenance of confidentiality and respect for patients' rights in the author's responsibilities document, publication agreement, and assignment of rights to Revista Española de Urgencias Emergencias.

Editor in Charge:

Elena Castejón-de la Encina.

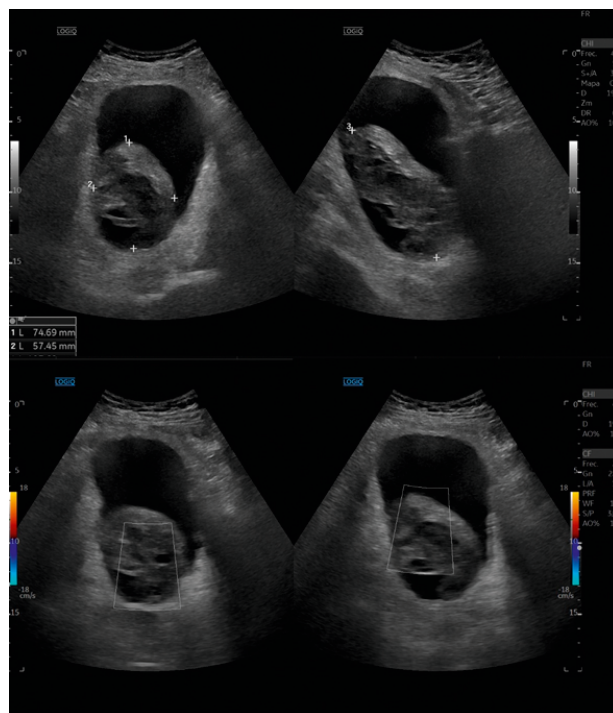


Figure 1.

was acute urinary retention due to blood clots with post-renal acute kidney injury.

The use of H₂O₂ has been described for more than 20 years as a treatment for wound debridement and irrigation.^{1,2} In recent years, it has also been used as a dental whitener and to improve endoscopic visualization in upper GI bleeding.³ Its safety is well established, and although rarely used, it is also effective for unblocking urinary catheters in hematuric patients — provided that pain from oxygen re-

lease is managed with first-line WHO analgesics or, in some cases, mild sedation.⁴ The instillation is performed with 3% H₂O₂ diluted in saline through the urinary catheter. This simple technique can prevent hospital admissions and invasive procedures, improving both patient satisfaction and the length of stay.

Note of the editors: This is a BOWMAN-generated English translation of the officially indexed Spanish-language article, which should be cited as *Rev Esp Urg Emerg.* 2024;3:68-69. In this translated version, the editors have supervised the process; however, it cannot be ruled out that some

errors resulting from the artificial intelligence translation process may have gone unnoticed.

REFERENCES

1. Epstein JA. Hydrogen peroxide for hemostasis. *Neurosurgery.* 1987;20:63.
2. Hankin FM, Campbell SE, Goldstein SA, Matthews LS. Hydrogen peroxide as a topical hemostatic agent. *Clin Orthop Relat Res.* 1984;(186):244-8.
3. Warlick CA, Mouli SK, Allaf ME, Wagner AA, Kavoussi LR. Bladder irrigation using hydrogen peroxide for clot evacuation. *Urology.* 2006;68(6):1331-2.
4. Xu M, Jin L, Shan Y, Zhu J, Xue B. A simple and effective method for bladder blood clot evacuation using hydrogen peroxide. *J Int Med Res.* 2020;48:300060520924546.